

# Neonatal Hemochromatosis: A Congenital Alloimmune Hepatitis

Peter F. Whitington, M.D.<sup>1</sup>

## ABSTRACT

Neonatal hemochromatosis (NH) is a rare and enigmatic disease that has been clinically defined as severe neonatal liver disease in association with extrahepatic siderosis. It recurs at an alarming rate in the offspring of certain women; the rate and pattern of recurrence led us to hypothesize that maternal alloimmunity is the likely cause at least of recurrent cases. This hypothesis led to a trial of gestational treatment to prevent the recurrence of severe NH, which has been highly successful adding strength to the alloimmune hypothesis. Laboratory proof of an alloimmune mechanism has been gained by reproducing the disease in a mouse model. NH should be suspected in any very sick newborn with evidence of liver disease and in cases of late intrauterine fetal demise. Given the pathology of the liver and the mechanism of liver injury, NH could best be classified as *congenital alloimmune hepatitis*.

**KEYWORDS:** Neonatal hemochromatosis, acute liver failure, alloimmune disease, cirrhosis, hepatitis

Neonatal hemochromatosis (NH) is clinically defined as severe neonatal liver disease in association with extrahepatic siderosis in a distribution similar to that seen in hereditary hemochromatosis.<sup>1-4</sup> Considerable evidence indicates that it is a gestational disease in which fetal liver injury is the dominant feature. Because of the abnormal accumulation of iron in liver and other tissues, it has been called *neonatal iron storage disease*, and because of its origins before birth, it has also been called *congenital hemochromatosis*. Until recently, there has been little understanding of the pathophysiology of NH including the mechanism of fetal liver injury. There is no evidence that NH is anyway related to the family of diseases that fall under the classification of *hereditary hemochromatosis*. Our recent investigations have provided evidence that many cases of NH are due to maternal alloimmunity directed at the fetal liver. Given the pathology of the liver and the mechanism of liver injury,

NH could best be classified as *congenital alloimmune hepatitis*.

## ETIOLOGY AND PATHOGENESIS

The name *hemochromatosis* implies that iron is involved in the pathogenesis of NH. Thus, a brief overview of the regulation of fetal iron homeostasis is indicated. The fetus regulates placental iron transport to ensure adequate iron for the growth and oxygen-carrying capacity needs of the fetus and newborn. The placenta acts as an active interface between the mother's huge iron pool and the highly controlled and relatively small fetal iron pool, ensuring adequate iron supply to the fetus and protecting against potentially toxic iron overload.<sup>5</sup> Concepts regarding how the flux of iron from mother to fetus is regulated are currently unfolding. It appears that many of the control mechanisms that function after birth to

<sup>1</sup>Department of Pediatrics, Northwestern University Feinberg School of Medicine, Children's Memorial Hospital, Chicago, Illinois.

Address for correspondence and reprint requests: Peter F. Whitington, M.D., 2300 Children's Plaza, Box 57, Chicago, IL 60614.

Pediatric Liver Disease: Translating Discoveries into Practice;

Guest Editor, Ronald J. Sokol, M.D.

Semin Liver Dis 2007;27:243-250. Copyright © 2007 by Thieme Medical Publishers, Inc., 333 Seventh Avenue, New York, NY 10001, USA. Tel: +1(212) 584-4662.

DOI 10.1055/s-2007-985069. ISSN 0272-8087.

control accrual of dietary iron (see review by Fleming and Bacon<sup>6</sup>) also function during fetal life, with the placental trophoblast functioning in analogy to the duodenal mucosa.<sup>7</sup> Ferroportin is highly expressed and colocalizes with hemochromatosis gene product (HFE) in placental trophoblast cells.<sup>8,9</sup> Ferroportin expression increases with gestational age in parallel with increasing iron needs of the fetus.<sup>9</sup> Fetal hepcidin evidently regulates fetal iron stores. Disruption of the hepcidin gene in the mouse results in a hemochromatosis phenotype,<sup>10</sup> and transgenic hepcidin-overexpressing mice are born profoundly anemic and iron-deficient.<sup>11</sup>

NH almost certainly does not result from iron overload. In contrast with hereditary hemochromatosis where iron overload is the primary event leading to liver injury developing over many years, it seems implausible that the severe liver injury observed in NH could be the result of iron overload taking place over only weeks of time. Furthermore, it has been suggested from clinical observations that liver disease appears to precede iron deposition in NH.<sup>12-14</sup> This degree of liver injury is not observed in juvenile hereditary hemochromatosis despite hepatic siderosis that is more severe than that seen in NH.<sup>15,16</sup> Juvenile hereditary hemochromatosis results from homozygous mutations in the genes for hemojuvelin or hepcidin, which in either case results in failure to express hepcidin.<sup>17</sup> Affected individuals would be expected to accumulate excess iron *in utero* just as the hepcidin knockout mice do, yet none have been described with neonatal liver disease. In addition, hepcidin knockout mice have no liver injury despite massive iron overload.<sup>10</sup> This and other evidence speaks strongly against iron overload being the primary event in the pathogenesis of NH.

It is not clear if iron overload results from liver injury in NH, indeed if it exists at all. Most cases show clear extrahepatic siderosis, a diagnostic hallmark of NH, and many have elevated serum iron indices. Yet, many affected babies are anemic. It is not known if newborns with NH are actually iron-loaded, which is to say that total body iron content has never been determined. In this model of disease where fetal liver injury is the primary insult, the hemochromatosis phenotype likely results from secondary iron deposition in extrahepatic tissues. There are two possibilities to consider in regard to the mechanism of siderosis in NH. The first possibility is that the fetus becomes iron-loaded due to poor control of iron flux across the placenta. Fetal hepcidin is involved in regulating placental ferroportin function, which is intimately involved in regulating maternal-fetal iron flux. It is reasonable to speculate that reduced hepcidin synthesis in the severely injured liver could lead to poor regulation of ferroportin in the placenta and to iron overload. The failure to regulate ferroportin could also contribute to the observed lack of macrophage and Kupffer cell iron. The second possibility is that the NH fetus is not actually iron-loaded but rather has an

abnormal but discrete deposition of iron in certain tissues. With severe liver injury, the central repository and distribution apparatus for iron in the fetus is impaired. The transferrin saturation is high in NH, so free (non-transferrin-bound) iron may be in excess. The tissues showing siderosis are those with a propensity to take up non-transferrin-bound iron from plasma. These mechanisms and possibly others deserve study.

The cause of fetal liver injury leading to the NH phenotype remains a point of debate. There is mounting evidence, however, in support of the hypothesis that most cases result from alloimmune liver injury.<sup>18</sup> The observation leading to the alloimmune hypothesis comes from the unusual pattern and high rate of recurrence in the progeny of affected women. After the index case, there is an ~60% to 80% probability that each subsequent baby born to that mother will be affected.<sup>19-21</sup> A woman may have unaffected offspring before having the first child with NH, but thereafter most pregnancies terminate in either a fetal loss or a child born with NH. There are several documented instances of a woman giving birth to affected babies with different male parentage, but not vice versa.<sup>19,21,22</sup> It has never been recorded that female siblings of women having a baby with NH themselves have had an affected baby. NH appears therefore to be congenital and familial but not hereditary. This pattern of recurrence is much like that of known materno-fetal alloimmune diseases.

The alloimmune hypothesis states that NH is an alloimmune gestational disease that leads to severe fetal liver injury and consequently to the NH phenotype.<sup>18</sup> Materno-fetal alloimmunity is mediated by IgG. Maternal antibodies of the IgG class (and only IgG) are actively transported across the placenta to the fetus from about the 18th week of gestation. The principle function of this process is to provide humoral immunity for the fetus and newborn against a broad array of microbiologic antigens to which there has been no exposure. The principle of alloimmunity involves exposure of a woman to a fetal antigen that she fails to recognize as "self," which results in sensitization and production of specific immunoglobulin of the IgG class capable of recognizing and binding to the antigen. In NH, the alloimmune target appears to be a hepatocyte cell surface antigen. In NH-sensitized mothers, transplacental passage of maternal IgG to the fetus (in this and subsequent pregnancies) is accompanied by movement of anti-fetal liver antigen IgG to the fetal circulation, where it binds to the liver antigen and results in immune injury of the fetal liver.

We have examined this mechanism of fetal liver injury in a mouse model.<sup>23</sup> It is known that human IgG administered by intraperitoneal injection to pregnant mice from midgestation forward is substantially transferred to the pups. In this model of passive alloimmunity, pregnant mice received injections of whole serum or IgG from women whose babies had bona fide NH.

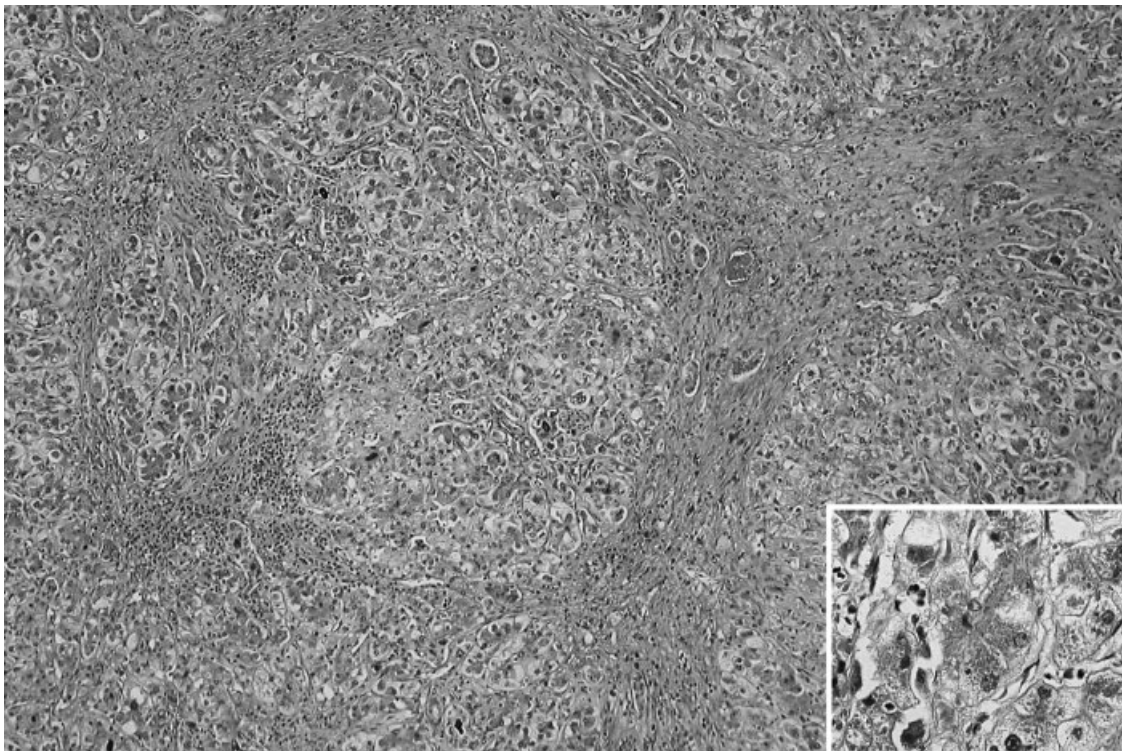
Compared with those injected with control sera, which were not different from saline-injected animals, injecting NH material resulted in markedly reduced litter size and increased numbers of stillbirths. Liver histology from E16 to P1 pups showed extensive hepatocyte injury/necrosis and increased lobular inflammation. No other organs or tissues were damaged. Excess iron could not be demonstrated by staining in liver or other tissues. Findings in this *in vivo* murine model of passive NH alloimmunity provide evidence of an alloimmune mechanism for NH-related liver injury. To determine the mechanism of NH-IgG mediated liver necrosis, NH-IgG was applied to fetal mouse hepatocytes in culture in the presence and absence of bovine complement. In the absence of complement, hepatocytes showed substantial human IgG bound to their surface, whereas control IgG did not bind. NH-IgG in presence of complement resulted in extensive cell necrosis, whereas control IgG did not. These *in vitro* findings suggest that NH-alloimmunity involves IgG binding to hepatocytes followed by complement-dependent cytotoxicity. Much additional work is needed to confirm these findings and to further elucidate the mechanisms of injury.

It is not known at present if all NH is alloimmune. It appears that the NH phenotype, at least early-onset liver failure and hepatic siderosis, can occasionally result from fetal liver injury due to genetic/metabolic

disease and perinatal infection.<sup>13,24,25</sup> Several groups continue to search for a gene locus whose mutation might cause NH.<sup>19,26</sup> Although there is reason to believe that the majority represents a humoral alloimmune fetal liver injury, a reliable serologic test for NH-associated antibody will be needed to prove this. It should be possible with such a test to determine if all cases of NH represent a single disease—alloimmune NH—or if there are some cases that are secondary to another, perhaps sporadic, fetal liver injury. This might explain the cases where NH does not recur for some women.

## PATHOLOGY

Autopsy specimens from stillbirths and newborns have provided most of the pathologic descriptions of the disease. The liver injury in NH is very severe and out of proportion to that seen in other forms of hemochromatosis.<sup>1,2</sup> Cirrhosis is evident in nearly all cases. Fibrosis is pronounced, particularly in the lobule and around the central vein. Regenerative nodules may be present. In some instances, almost no hepatocytes remain. The residual and/or regenerating hepatocytes may exhibit either giant cell or pseudoacinar transformation with canalicular bile plugs. The histopathology often resembles that seen in acute and subacute liver failure in older individuals (Fig. 1). Residual



**Figure 1** Severely damaged liver in a 6-week-old baby with NH who had a liver transplant due to liver failure. The main image shows several areas of parenchymal collapse and scarring, with formation of thick fibrous septa and parenchymal regenerative nodules. The inset shows severely injured hepatocytes, which show marked variation in size and shape, pseudoacinar transformation, and severe cholestasis. (H&E-stained sections. Original magnifications: main image,  $\times 100$ ; inset,  $\times 400$ .)

hepatocytes often show siderosis while Kupffer cells are spared. The siderosis is coarsely granular, which is in contrast with the hazy iron staining of normal newborn liver. Considerable acute and chronic inflammation is usually evident.<sup>27</sup>

Siderosis may affect any of several tissues outside the liver.<sup>2,3,28,29</sup> The most consistently affected are the acinar epithelium of the exocrine pancreas, myocardium, the epithelia of the thyroid follicles, and the mucosal ("minor salivary") glands of the oronasopharynx and respiratory tree. Less affected are gastric and Brunner glands, parathyroid glands, choroid plexus, thymus (Hassall corpuscles), pancreatic islets, the adenohypophysis, and chondrocytes in hyaline cartilage. The spleen, lymph nodes, and bone marrow contain comparatively trivial quantities of stainable iron.

Occasionally, severely affected babies exhibit renal hypoplasia, with dysgenesis of proximal tubules.<sup>30,31</sup> Correlation with the process of normal renal development dates this arrest of renal development to ~24 weeks gestation. It is believed that this final stage of renal development is dependent upon liver function, and therefore the disordered development dates liver failure to the late second and early third trimesters.

## SIGNS, SYMPTOMS, AND LABORATORY FINDINGS

NH is nearly always accompanied by severe fetal liver injury, and one of its most common presentations is late-second and third trimester fetal loss as evidenced by the gestational histories of women who have had a baby diagnosed with NH. Most affected live-born babies show evidence of fetal insult (i.e., intrauterine growth restriction [IUGR] and oligohydramnios), and premature birth is common.<sup>1</sup> Liver disease is generally apparent within hours of birth, and NH is one of the most commonly recognized causes of liver failure in the neonate.<sup>32-34</sup> In rare cases, the liver disease takes a prolonged course and is manifest days to weeks after birth.<sup>35</sup> There is a spectrum of disease, and some infants recover with supportive care.<sup>36,37</sup> Indeed, it may be that some "affected" babies have no clinical disease. Twins may have disparate clinical findings, with one severely affected and the other minimally so.<sup>38</sup>

The presenting findings are those of liver failure and usually multiorgan failure. Affected babies are frequently diagnosed as having overwhelming sepsis of the newborn even with negative cultures. Hypoglycemia, marked coagulopathy, hypoalbuminemia and edema with or without ascites, and oliguria are prominent features. Affected babies are sometimes said to have "nonimmune hydrops" due to the anasarca they exhibit. Jaundice develops during the first few days after birth. Most cases exhibit significant elevations of both con-

jugated and nonconjugated bilirubin, with total bilirubin levels often exceeding 30 mg/dL. Serum aminotransferase concentrations are disproportionately low for the degree of hepatic injury, whereas circulating concentrations of  $\alpha$ -fetoprotein (AFP) are characteristically very high, usually 100,000 to 600,000 ng/mL (normal newborn values < 80,000 ng/mL).<sup>1,21</sup> Elevated concentrations of AFP in NH could be due to failure to downregulate the synthesis of AFP, which is a normal part of the switch from a fetal to a neonatal metabolic pattern occurring near the end of pregnancy. We hypothesize that the low aminotransferase activities reflect a similar failure of the perinatal metabolic switch, which normally results in turning on gluconeogenic pathways that include the aminotransferases. Exhaustion of hepatocyte mass might also contribute to the low levels; however, infants who survive with medical therapy and thus obviously do not have exhausted hepatocyte mass also have low serum aminotransferase levels. In these babies, recovery is often heralded by increasing serum aminotransferase levels. Studies of iron status often show hypersaturation of available transferrin, with hypotransferrinemia and hyperferritinemia (values > 800 ng/mL), which though characteristic in NH are nonspecific in liver disease of the newborn infant.<sup>39</sup> The low transferrin levels probably reflect severe liver disease. Notably, patients may receive the diagnosis of tyrosinemia based on elevated serum tyrosine levels, which are reflective of failed hepatic metabolic function. However, succinylacetone is absent in the urine. Also, characteristic of NH is persistent patency of the ductus venosus, which can be demonstrated by sonography,<sup>1</sup> the cause of which is unclear.

## DIAGNOSIS

NH should be suspected in infants who manifest liver disease antenatally or very shortly after birth. It should also be suspected in unexplained cases of stillbirth. Demonstration of extrahepatic siderosis is currently necessary to prove the diagnosis. No other disease of the newborn demonstrates the combination of severe liver disease and extrahepatic siderosis, and thus the combination of findings is absolutely diagnostic. Caution should be exercised in evaluating hepatocyte siderosis for the purpose of diagnosing NH. Finding siderosis in the liver is not diagnostic. The normal newborn liver contains sufficient stainable iron to be confused with pathologic siderosis, although they are qualitatively different to the eyes of experienced pathologists. Furthermore, pathologic hepatic siderosis has been described in several neonatal liver diseases; however none in combination with extrahepatic siderosis. The absence of stainable iron in the liver does not exclude the diagnosis of NH as in many cases few if any hepatocytes remain, and hepatic siderosis in NH involves hepatocytes exclusively.

NH is often diagnosed at autopsy, where siderosis of many tissues can be demonstrated if looked for. Proper stains for iron (Prussian blue, Perl's stain) should be performed on the tissues typically involved (see "Pathology" section above) when autopsy is performed on any baby with liver failure or suspected liver disease and in unexplained stillbirths. Failure to do so has resulted in many missed diagnoses with dire consequences for subsequent pregnancies of affected women. Demonstration of extrahepatic siderosis in living babies can be by tissue biopsy or by magnetic resonance imaging (MRI) (Fig. 2). Biopsy of the oral mucosa is a clinically useful approach to obtain glandular tissue in which to demonstrate siderosis.<sup>28,40</sup> Differences in magnetic susceptibility between iron-laden and normal tissues on T2-weighted MRI can document siderosis of various tissues, particularly the pancreas and liver.<sup>41,42</sup> The diagnostic utility of these approaches has never been formally evaluated. Oral mucosal biopsy often fails because an inadequate specimen not containing submucosal glands is obtained. Experience suggests that adequate biopsies contain some stainable iron (any amount is abnormal) in more than two thirds of cases with severe liver disease,<sup>40</sup> whereas MRI demonstrates abnormal iron distribution in ~90% of such cases.

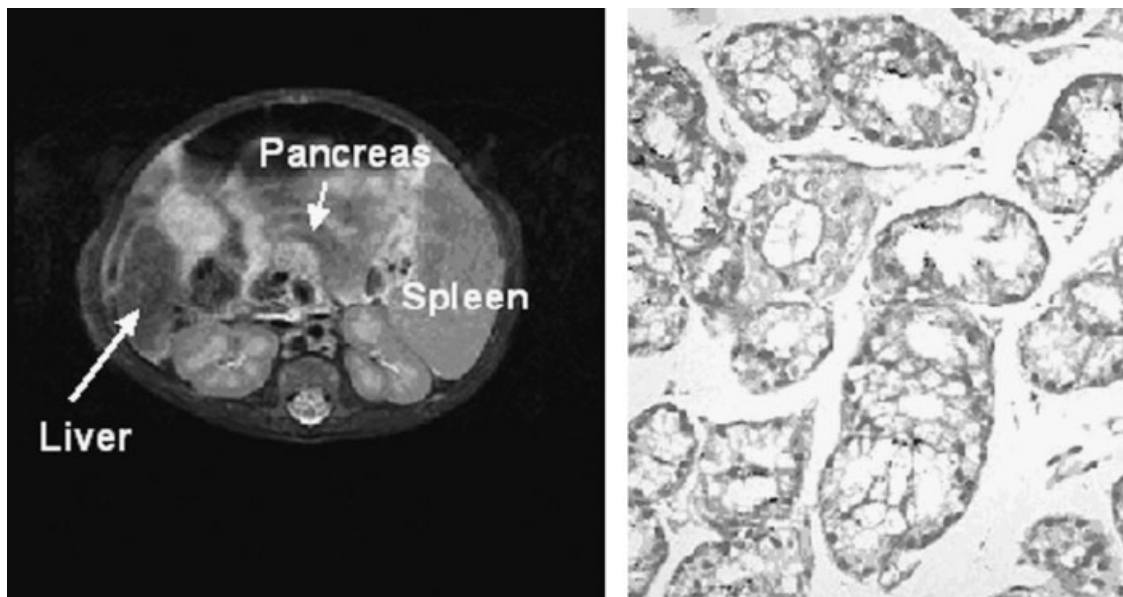
A question remains whether NH can be diagnosed in the absence of extrahepatic siderosis and/or severe liver disease. Our growing experience drawn from sibships suggests that there is a spectrum of both findings, assuming that severe liver disease in a sibling of a baby with NH proved by standard criteria is due to NH. We have seen acute liver failure with confluent hepatic

necrosis in a 21-week fetus in which no siderosis could be demonstrated in liver or other tissues. Conversely, fraternal twins of affected babies have been minimally affected with no clinical liver disease.<sup>38</sup> Finally, we have seen autopsy materials from fetal products of late intrauterine demise where autolysis and maceration prevented diagnosis of NH-associated liver disease and no siderosis was detectable, yet subsequent offspring of the affected women had NH proven by standard criteria. Better diagnostic tests and/or criteria are needed before the full spectrum of this disease can be recognized.

Because a fetus in a mother who has borne an infant with NH is at risk, antenatal diagnosis has been attempted. Fetal sonography can provide indirect evidence of liver injury, in particular placental or fetal edema, in the third trimester. MRI has not been useful in identifying hemochromatotic siderosis in utero.

### TREATMENT AND OUTCOME

The prognosis in severe NH is generally very poor.<sup>1,34,43,44</sup> The average life expectancy of the average severely affected baby is days to a few weeks. NH is a frequent indication for liver transplantation in the first 3 months of life.<sup>32,33,45-47</sup> When performed for NH, the difficulties attendant to transplanting newborns are frequently compounded by prematurity, small size for gestational age, and multiorgan failure. Furthermore, it is clear that babies with clinical liver failure due to NH can fully recover with medical support.<sup>36,37,43,44</sup> Thus, caution is indicated when considering treating an affected baby with liver transplantation.



**Figure 2** The diagnosis of NH depends on demonstrating iron in extrahepatic tissue. The MRI (T2-weighted) and the iron-stained section of buccal mucosa from a newborn with NH are demonstrated. The MRI (left panel) demonstrates attenuated signal (dark) from the liver and pancreas relative to the spleen, indicating increased iron content. The buccal biopsy shows iron deposition in epithelium of submucosal glands (black flecks in glandular epithelium). Both findings are diagnostic of NH in a baby with evidence of liver disease or liver failure. This baby survived with medical therapy.

Current medical treatment is less than satisfactory. A cocktail containing both antioxidants and an iron chelator has been used to treat NH.<sup>1,43,48</sup> Success rates with medical treatment have been reported to be 10% to 20%, and it is not clear what factors determine a successful outcome. Within the spectrum of severe NH, it may be that patients with more hepatic reserve profit from it, whereas more severely affected patients fail to respond. This therapy was based on the hypothesis that oxidative injury due to iron overload was central to disease pathogenesis, which appears not to be the case. Treatment of neonates severely affected with alloimmune (i.e., thrombocytopenia) and passive autoimmune (i.e., lupus heart block) diseases is based on one principle: remove the maternal IgG to preclude further immune injury. A rational approach to treating NH based on its alloimmune causation would be to combine the cocktail with double volume exchange transfusion (with blood reconstituted from packed red blood cells and fresh-frozen plasma from unrelated donors) to remove the maternal alloantibody followed by administration of intravenous immunoglobulin to restore broad humoral immunity. This approach might be expected to reduce ongoing immune-mediated injury and perhaps improve function but would not necessarily be effective in reversing advanced disease including cirrhosis. A limited experience with this approach suggests that it offers some improvement in outcome.<sup>49</sup>

Limited published experience exists with regard to the outcome of babies who survive severe NH with medical therapy. Our experience with 6 such babies suggests that full recovery is likely. All were in clinical liver failure shortly after birth and had clinical evidence of cirrhosis including a hard liver, ascites, and caput medusa. All were treated with the antioxidant/chelation cocktail. Four of the 6 experienced at least 1 episode of sepsis possibly related to the use of desferrioxamine, which is toxic to neutrophils. Recovery from liver failure to ability to discharge to home varied from 1 to 4 months. All 6 babies ultimately recovered fully with no residual clinical liver disease after a period of 1 to 2 years. In a unique experience, 2 of these babies who are siblings underwent liver biopsy as neonates and again after 2 to 4 years.<sup>50</sup> The initial biopsies demonstrated typical histology of severe NH with a pathologic diagnosis of cirrhosis. The repeat biopsies demonstrated normal histology with no pathologic findings. Although a very limited experience, this suggests that the neonatal liver affected with NH is quite plastic and capable of recovery even from severe injury.

Accumulating experience indicates that recurrence of severe NH can be prevented by treatment during gestation.<sup>21,51</sup> The treatment consists of intravenous immunoglobulin (IVIG) derived from pooled serum of multiple donors administered weekly at a dose of 1 g/kg body weight from the 18th week until the end of gestation. This is a modification of the

treatment commonly used to reduce the severity of other gestational alloimmune diseases. Women whose most recent gestation was affected with proven NH should be treated in lieu of any other marker for high risk of recurrence. At the time of writing, 46 babies have been born to mothers receiving gestational treatment. No IUGR, fetal liver disease, or other evidence of fetal distress has been detected in any case. Few babies born after gestational treatment have had significant clinical liver disease. However, biochemical evidence suggests that ~80% of babies were affected: elevated serum AFP (range, 100,820 to 670,000 ng/mL) and/or elevated serum ferritin (range, 1250 to 15,948 ng/mL). This growing experience suggests that treatment with high-dose IVIG during gestation modifies recurrent NH so that it is not lethal to the fetus or the newborn.

## CONCLUSION

NH is a prominent cause of severe fetal liver injury and should be suspected in cases of late intrauterine fetal demise in the absence of other definable cause. It should be suspected in any very sick newborn with evidence of liver disease as it is the cause of most cases of newborn liver failure and/or cirrhosis. Diagnosis is confirmed by demonstrating extrahepatic siderosis. However, there is a spectrum of NH-related phenotypes that can include minimally affected siblings of affected babies and acute liver failure in the absence of extrahepatic siderosis. NH appears to be the manifestation of maternal alloimmunity in many cases. The risk for recurrence in subsequent offspring of an affected woman is very high, though prevention of recurrent severe NH by gestational treatment using IVIG has been very effective. Thus, it is imperative to diagnose NH in an affected fetus or baby through proper study including autopsy. Ongoing research should lead to better approaches to diagnosis and treatment.

## ABBREVIATIONS

AFP	$\alpha$ -fetoprotein
H&E	hematoxylin and eosin
HFE	hemochromatosis gene
IgG	immunoglobulin G
IUGR	intrauterine growth restriction
IVIG	intravenous immunoglobulin
MRI	magnetic resonance imaging
NH	neonatal hemochromatosis

## REFERENCES

1. Knisely AS, Mieli-Vergani G, Whittington PF. Neonatal hemochromatosis. *Gastroenterol Clin North Am* 2003;32: 877-889

2. Knisely AS. Neonatal hemochromatosis. *Adv Pediatr* 1992; 39:383–403
3. Goldfischer S, Grotsky HW, Chang CH, et al. Idiopathic neonatal iron storage involving the liver, pancreas, heart, and endocrine and exocrine glands. *Hepatology* 1981;1:58–64
4. Murray KF, Kowdley KV. Neonatal hemochromatosis. *Pediatrics* 2001;108:960–964
5. van Dijk JP. Regulatory aspects of placental iron transfer: a comparative study. *Placenta* 1988;9:215–226
6. Fleming RE, Bacon BR. Orchestration of iron homeostasis. *N Engl J Med* 2005;352:1741–1744
7. Georgieff MK, Wobken JK, Welle J, Burdo JR, Connor JR. Identification and localization of divalent metal transporter-1 (DMT-1) in term human placenta. *Placenta* 2000;21:799–804
8. Bradley J, Leibold EA, Harris ZL, et al. Influence of gestational age and fetal iron status on IRP activity and iron transporter protein expression in third-trimester human placenta. *Am J Physiol Regul Integr Comp Physiol* 2004; 287:R894–R901
9. Gruper Y, Bar J, Bacharach E, Ehrlich R. Transferrin receptor co-localizes and interacts with the hemochromatosis factor (HFE) and the divalent metal transporter-1 (DMT1) in trophoblast cells. *J Cell Physiol* 2005;204:901–912
10. Nicolas G, Bennoun M, Devaux I, et al. Lack of hepcidin gene expression and severe tissue iron overload in upstream stimulatory factor 2 (USF2) knockout mice. *Proc Natl Acad Sci U S A* 2001;98:8780–8785
11. Nicolas G, Bennoun M, Porteu A, et al. Severe iron deficiency anemia in transgenic mice expressing liver hepcidin. *Proc Natl Acad Sci U S A* 2002;99:4596–4601
12. Hoogstraten J, de Sa DJ, Knisely AS. Fetal liver disease may precede extrahepatic siderosis in neonatal hemochromatosis. *Gastroenterology* 1990;98:1699–1701
13. Kershnik MM, Knisely AS, Sun CC, Andrews JM, Wittwer CT. Cytomegalovirus infection, fetal liver disease, and neonatal hemochromatosis. *Hum Pathol* 1992;23:1075–1080
14. Witzleben CL, Uri A. Perinatal hemochromatosis: entity or end result? *Hum Pathol* 1989;20:335–340
15. Camaschella C, Roetto A, De Gobbi M. Juvenile hemochromatosis. *Semin Hematol* 2002;39:242–248
16. De Gobbi M, Roetto A, Piperno A, et al. Natural history of juvenile haemochromatosis. *Br J Haematol* 2002;117:973–979
17. Niederkofler V, Salie R, Arber S. Hemojuvelin is essential for dietary iron sensing, and its mutation leads to severe iron overload. *J Clin Invest* 2005;115:2180–2186
18. Whittington PF, Malladi P. Neonatal hemochromatosis: is it an alloimmune disease? *J Pediatr Gastroenterol Nutr* 2005; 40:544–549
19. Kelly AL, Lunt PW, Rodrigues F, et al. Classification and genetic features of neonatal haemochromatosis: a study of 27 affected pedigrees and molecular analysis of genes implicated in iron metabolism. *J Med Genet* 2001;38:599–610
20. Shneider BL. Genetic counseling in neonatal hemochromatosis. *J Pediatr Gastroenterol Nutr* 2002;34:328
21. Whittington PF, Hibbard JU. High-dose immunoglobulin during pregnancy for recurrent neonatal haemochromatosis. *Lancet* 2004;364:1690–1698
22. Allen KJ, Hart J, Whittington PF. Spectrum of outcomes in family of male siblings with neonatal hemochromatosis [abstract]. *J Pediatr Gastroenterol Nutr* 1996;23:352
23. Malladi P, Wang H, Pan X, Kohli R, Whittington PF. The pathogenesis of neonatal hemochromatosis involves maternal IGG alloantibody mediated complement-dependent hepatocytolysis and necrosis. *Hepatology* 2006;44:56A
24. Shneider BL, Setchell KD, Whittington PF, Neilson KA, Suchy FJ. Delta 4-3-oxosteroid 5 beta-reductase deficiency causing neonatal liver failure and hemochromatosis. *J Pediatr* 1994;124:234–238
25. Visapaa I, Fellman V, Vesa J, et al. GRACILE syndrome, a lethal metabolic disorder with iron overload, is caused by a point mutation in BCS1L. *Am J Hum Genet* 2002;71:863–876
26. Cox TM, Halsall DJ. Hemochromatosis: neonatal and young subjects. *Blood Cells Mol Dis* 2002;29:411–417
27. Silver MM, Valberg LS, Cutz E, Lines LD, Phillips MJ. Hepatic morphology and iron quantitation in perinatal hemochromatosis: comparison with a large perinatal control population, including cases with chronic liver disease. *Am J Pathol* 1993;143:1312–1325
28. Knisely AS, O'Shea PA, Stocks JF, Dimmick JE. Oropharyngeal and upper respiratory tract mucosal-gland siderosis in neonatal hemochromatosis: an approach to biopsy diagnosis. *J Pediatr* 1988;113:871–874
29. Silver MM, Beverley DW, Valberg LS, Cutz E, Phillips MJ, Shaheed WA. Perinatal hemochromatosis: clinical, morphologic, and quantitative iron studies. *Am J Pathol* 1987;128: 538–554
30. Johal JS, Thorp JW, Oyer CE. Neonatal hemochromatosis, renal tubular dysgenesis, and hypocalvaria in a neonate. *Pediatr Dev Pathol* 1998;1:433–437
31. Morris S, Akima S, Dahlstrom JE, Ellwood D, Kent A, Falk MC. Renal tubular dysgenesis and neonatal hemochromatosis without pulmonary hypoplasia. *Pediatr Nephrol* 2004; 19:341–344
32. Rodrigues F, Kallas M, Nash R, et al. Neonatal hemochromatosis: medical treatment vs. transplantation: the King's experience. *Liver Transpl* 2005;11:1417–1424
33. Durand P, Debray D, Mandel R, et al. Acute liver failure in infancy: a 14-year experience of a pediatric liver transplantation center. *J Pediatr* 2001;139:871–876
34. Shneider BL. Neonatal liver failure. *Curr Opin Pediatr* 1996;8:495–501
35. Ku SW, Luk IS, Yuen MK, Wong CP. Subacute hepatic failure after the perinatal period with haemochromatotic siderosis at the age of 11 months: an unusual perspective on neonatal haemochromatosis. *Acta Paediatr* 2002;91:856–858
36. Inui A, Fujisawa T, Kubo T, Sogo T, Komatsu H, Kagata Y. A case of neonatal hemochromatosis-like liver failure with spontaneous remission. *J Pediatr Gastroenterol Nutr* 2005; 40:374–377
37. Bellini C, Mazzella M, Scopesi F, Serra G. Spontaneous recovery in neonatal hemochromatosis. *J Hepatol* 2004;41: 882–883
38. Ekong UD, Kelly S, Whittington PF. Disparate clinical presentation of neonatal hemochromatosis in twins. *Pediatrics* 2005;116:e880–e884
39. Lee WS, McKiernan PJ, Kelly DA. Serum ferritin level in neonatal fulminant liver failure. *Arch Dis Child Fetal Neonatal Ed* 2001;85:F226

40. Smith SR, Shneider BL, Magid M, Martin G, Rothschild M. Minor salivary gland biopsy in neonatal hemochromatosis. *Arch Otolaryngol Head Neck Surg* 2004;130:760-763
41. Hayes AM, Jaramillo D, Levy HL, Knisely AS. Neonatal hemochromatosis: diagnosis with MR imaging. *AJR Am J Roentgenol* 1992;159:623-625
42. Udell IW, Barshes NR, Voloyiannis T, et al. Neonatal hemochromatosis: radiographical and histological signs. *Liver Transpl* 2005;11:998-1000
43. Flynn DM, Mohan N, McKiernan P, et al. Progress in treatment and outcome for children with neonatal haemochromatosis. *Arch Dis Child Fetal Neonatal Ed* 2003;88:F124-F127
44. Vohra P, Haller C, Emre S, et al. Neonatal hemochromatosis: the importance of early recognition of liver failure. *J Pediatr* 2000;136:537-541
45. Sundaram SS, Alonso EM, Whittington PF. Liver transplantation in neonates. *Liver Transpl* 2003;9:783-788
46. Woodle ES, Millis JM, So SK, et al. Liver transplantation in the first three months of life. *Transplantation* 1998;66:606-609
47. Rand EB, McClenathan DT, Whittington PF. Neonatal hemochromatosis: report of successful orthotopic liver transplantation. *J Pediatr Gastroenterol Nutr* 1992;15:325-329
48. Sigurdsson L, Reyes J, Kocoshis SA, Hansen TW, Rosh J, Knisely AS. Neonatal hemochromatosis: outcomes of pharmacologic and surgical therapies. *J Pediatr Gastroenterol Nutr* 1998;26:85-89
49. Rand EB, Karpen SJ, Zweiner J, et al. Treatment of neonatal hemochromatosis based on alloimmune causation. *Hepatology* 2006;44:435A
50. Ekong U, Melin-Aldana H, Whittington PF. Reversal of cirrhosis in two children with neonatal hemochromatosis. *J Pediatr Gastroenterol Nutr* 2007. In press
51. Whittington PF. Fetal and infantile hemochromatosis. *Hepatology* 2006;43:654-660